



Heart and Soul Animal Urgent Care
315 NE Killingsworth Street
Portland, OR 97211
United States
(503) 749-9400

GENERATED: 8/11/2022 12:33 PM

Client Information

Michelle Bailey
Portland, OR
97217 (503)

Patient Information

<u>Name</u>	Toots	<u>Species</u>	Canine	<u>Weight</u>	5.7 KG
<u>Sex</u>	Male Neutered	<u>Breed</u>	Maltese	<u>Microchip</u>	NONE
<u>Status</u>	Active	<u>DOB</u>	5/10/2010		
<u>Id</u>	15847	<u>Age</u>	12 years 3 months		
<u>Color</u>	white and brown	<u>Tag</u>	NONE		

Weight History

<u>Date</u>	<u>Weight</u>
5/10/2022	5.7 KG

Medical Chart from 1/1/2000 - 8/10/2022

Service on 5/10/2022

5/10/2022 6:51 PM Document WO, Triage, IHBW.pdf

Patient ID :15847 Tuesday, May 10, 2022
 Toots Michelle Bailey
 12 years (503) 964-3825
 5/10/2010
 Male Neutered
 Canine - Maltese
 0

Sarah Hunter, DVM		Time: 1240
Presenting Concern: Hyporexia droolings		
Caution? Y / N		Sedation needed? Y / N
ER Drug Sheet printed by:		
IVC :		YES / NO
Gauge	Placement	Initials Time

ALERTS: no rDVM

Diagnostics

Labs	
BW	CBC/Chem IN / OUT
PCV: 52%	TP: 8.0g/dl BG:
Time/Initials: KA/DRU 12:46	
UA	IN / OUT Cysto / FC
Time/Initials:	
Fecal	IN / OUT KIT TGH
Time/Initials:	
Cytology	IN / OUT
Time/Initials:	

Medications

Drug	mg	mL	Route	Time	Initials	Logged
						<input type="checkbox"/>
						<input type="checkbox"/>
						<input type="checkbox"/>
						<input type="checkbox"/>
						<input type="checkbox"/>
						<input type="checkbox"/>
						<input type="checkbox"/>

Additional Vitals

BP	Method	Cuff/Limb
SP02	Other:	
Time/Initials:		

Fluids

Type	Amount	Route	Time/Initials

Radiographs

Type	STAT Y / N	Time/Initials
History		

Additional Treatments/Diagnostics

Order	Description	Time	Initial
1			
2			
3			
4			
5			
6			
7			
8			
9			

Date: 5/10 Parking spot: _____
 Time: 11:27

Temp: 102.3
 Pulse: 160 / Min.
 RR: 80 / Min. shake
 MM: Pal CRT: <2
 Wt: 5.70 Kg

CPR/DNR _____
 IVG/MEDS _____

YES SED / ASK 1st

NAME: TODTS AGE: 12y

K9 / Fel M / F Altered Y/N

(SERVICE DOG) - Silver Akita

History: HYPOREXIC 1.5 WK / 2d ANOREXIC
PROOILING 1 WK POSS TEETH ISSUES

ENVIRONMENTAL: NOT ALLOWED @ WORK 3MO
MOVED ACROSS COUNTRY 3MO

Tongue hanging

FB - NO / NO TOXINS / NO WATER

C/S/N/D C/S-NO V/D-NO

Urinating/Defecating WNL 97

Eating/Drinking NO D/YES

Indoor/Outdoor _____

Activity level WNL: Yes No lower energy

VAX UTD: Y/N ? IF HEALTHY VAX

Current Medications: NO

Previous Medical HX: NO

Other pets in the home: Fel: _____ K9: _____ Other: NO

VetScan HM5 v2.31

Sample ID
Patient ID
Type

03082 Name
15847 Age
Dog Gender

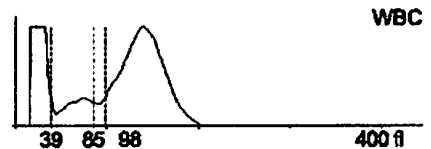

Toots
12 y
Neutered

Test Date
Report Date
Doctor


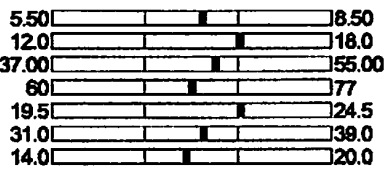
05/10/2022 11:20 AM Serial No.
05/10/2022 11:31 AM

360011890

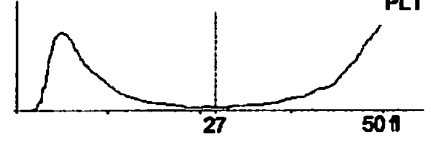
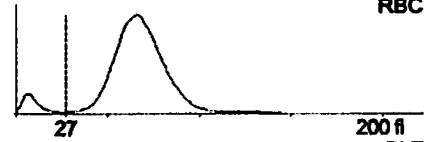
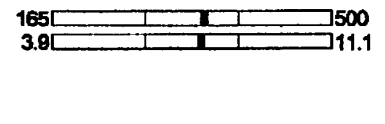
WBC	5.09 - 10 ⁹ /l
LYM	0.79 - 10 ⁹ /l
MON	0.24 10 ⁹ /l
NEU	3.90 10 ⁹ /l
EOS	0.11 10 ⁹ /l
BAS	0.05 10 ⁹ /l
LYM%	15.5 %
MON%	4.8 %
NEU%	78.7 %
EOS%	2.1 %
BAS%	1.0 %



RBC	7.38 10 ¹² /l
HGB	18.3+ g/dl
HCT	50.72 %
MCV	69 fl
MCH	24.8+ pg
MCHC	36.1 g/dl
RDWc	16.7 %
RDWs	44.5 fl



PLT	377 10 ⁹ /l
MPV	8.2 fl
PCT	0.31 %
PDWc	34.1 %
PDWs	10.9 fl



PrVW	376/379
PrVR	362/364
PrVE	305/310
WBC Lyse	0.55 ml
Lyse 2	3.50 ml

VetScan VS2

Comprehensive Diagnostic
10 May 2022 12:43 PM
Sample Type: Dog

Patient ID: 15847
Rotor Lot Number: 2024AA0
Serial Number: 0000V32935

ALB 3.7 g/dL	2.5	4.4
ALP 27 U/L	20	150
ALT 18 U/L	10	118
AMY 611 U/L	200	1200
IBIL <0.1- mg/dL	0.1	0.6
BUN 11 mg/dL	7	25
CA 10.7 mg/dL	8.6	11.8
PHOS 2.9 mg/dL	2.9	8.6
CRE 0.7 mg/dL	0.3	1.4

GLU 108 mg/dL	60	110
NA+ 150 mmol/L	138	180
K+ 3.7- mmol/l	3.7	5.8
TP 7.7 g/dL	5.4	8.2
GLOB 3.9 g/dL	2.3	5.2

QC OK
HEM 1+ LIP 0 ICT 0

Weight	5.7 KG (5.7 KG)
Temperature	102.3°F By Rectal
Heart Rate	160
Respiratory Rate	50
CRT	<2
Mucous Membrane	PINK

History

P presents with Hyporexia and drooling/foaming at the mouth for 1.5wk. O suspects possible teeth issues. Tongue hanging out more. No know fb. No known fish/toxins exposure. C/S-NO V/D-NO U/D-WNL. E/D-WNL. Activity: Lower energy. VAX unsure if UTD. Would like P vaxxed if applicable. No current meds. No previous med hx. Environmental change: moved across the country 3 mo ago.

CPR / YES SED / IVC-MEDS-ASK

SL 11:58

No Answer Given

Attitude QAR--Quiet, Alert, Responsive

Body Condition Score (BSC 1-9) 5 of 9 **NORMAL CONDITION** -

Body weight is ideal, Ribs palpable without excess fat covering. Waist observed behind ribs when viewed from above. Abdomen tucked up when viewed.

Integument (skin) Abnormalities Noted **ABNORMAL CONDITION** -Thinning hair coat over dorsum.

Eyes Corneas clear, pupils normal size and symmetrical, pupillary reflexes normal, no ocular discharge. **NORMAL CONDITION** Lenticular sclerosis **NORMAL CONDITION** - *Lenticular sclerosis* is considered a normal change in the lens associated with aging in dogs, and is observed as a cloudiness or bluish discoloration of both eyes. Vision does not appear to be significantly affected in dogs diagnosed with lenticular sclerosis. This condition is not the same as *cataracts*.

Ears No abnormal findings **NORMAL CONDITION**

Nose/Throat No nasal discharge or other abnormalities observed **NORMAL CONDITION**

Oral Cavity / Dental Periodontal Disease (Stage 1-4) - Stage: 4 with severe halitosis and multiple mobile teeth

Cardiovascular Cardiac abnormalities noted **ABNORMAL CONDITION** -Grade 2-3/6 left systolic murmur

Respiratory Respiratory rate and rhythm normal. Normal bronchovesicular sounds upon chest auscultation **NORMAL CONDITION**

Gastrointestinal No history or signs of vomiting or diarrhea. **NORMAL CONDITION**

Abdominal Palpation The abdomen is comfortable upon palpation and no overt mass effects or fluid waves are noted. **NORMAL CONDITION**

Urogenital No overt urogenital abnormalities are noted. **NORMAL CONDITION**

Lymphatics Lymph nodes are palpably normal in size and consistency. No evidence of lymph node enlargement is noted. **NORMAL CONDITION**

Musculoskeletal No overt gait deficits. No overt abnormalities upon palpation of limbs. **NORMAL CONDITION**

Neurological Neurologically appropriate. No overt cranial nerve deficits or proprioceptive deficits. **NORMAL CONDITION**

Assessment

1. Hyporexia, lethargy x ~2 weeks - r/o CKD, hepatopathy, pancreatitis, neoplasia, periodontal disease, open

Plan

Discussed exam findings and ddx with O via phone. While periodontal disease may be responsible for symptoms, would hate to overlook for serious systemic disease. Recommended CBC/chemistry and radiographs. O approved bloodwork only.

Diagnostics:

- 1. CBC:
--Mild lymphopenia (0.79 K/ul)
- 2. Chemistry: nsf
- 3. PCV/TS: 52%/8.0 g/dl

Client update post-bloodwork: Discussed bloodwork fairly unremarkable. This does not r/o every diagnosis, including neoplasia, but does take a lot off the list. Reasonable to proceed with anesthetized dental cleaning with extractions to see if this improves appetite. If Toots clinically becomes worse (completely anorexic, VD, more lethargic), should recheck to discuss additional diagnostics including imaging. O is new to town and working on limited budget - recommended calling GPs to set up relationship sooner than later. Also provided Forever Pet Dental as option to consider.

Sarah Hunter, DVM

5/10/2022 12:38 PM	Procedure	Examination & Assessment	Sarah Hunter, D.V.M.
5/10/2022 12:38 PM	Lab	Abaxis Complete Blood Count (CBC)	Sarah Hunter, D.V.M.
5/10/2022 12:38 PM	Lab	Abaxis Comprehensive Diagnostic Profile	Sarah Hunter, D.V.M.

Abaxis Lab Results						
Result Date: 5/10/2022						
Test	Value	Range	Units	Status	Comments	
CBC - HM5 Pack						
WBC	5.09	6.00 - 17.00	10 ⁹ /l	LOW	-	
RBC	7.38	5.50 - 8.50	10 ¹² /l			
HGB	18.3	12.0 - 18.0	g/dl	HIGH	+	
HCT	50.72	37.00 - 55.00	%			
MCV	69	60 - 77	fl			
MCH	24.8	19.5 - 24.5	pg	HIGH	+	
MCHC	36.1	31.0 - 39.0	g/dl			
PLT	377	165 - 500	10 ⁹ /l			
PCT	0.31		%			
MPV	8.2	3.9 - 11.1	fl			
PDWs	10.9		fl			
PDWc	34.1		%			
RDWs	44.5		fl			
RDWc	16.7	14.0 - 20.0	%			
LYM	0.79	1.00 - 4.80	10 ⁹ /l	LOW	-	
MON	0.24	0.20 - 1.50	10 ⁹ /l			
NEU	3.90	3.00 - 12.00	10 ⁹ /l			
LY%	15.5	0.0 - 100.0	%			
MO%	4.8	0.0 - 100.0	%			
NE%	76.7	0.0 - 100.0	%			
EOS	0.11	0.00 - 0.80	10 ⁹ /l			

Abaxis Lab Results

Result Date: 5/10/2022

Test	Value	Range	Units	Status	Comments
EO%	2.1	0.0 - 100.0	%		
BAS	0.05	0.00 - 0.40	10 ⁹ /l		
BA%	1.0	0.0 - 100.0	%		
CDP - Comprehensive Diagnostic					
ALB	3.7	2.5 - 4.4	g/dL		
ALP	27	20 - 150	U/L		
ALT	18	10 - 118	U/L		
AMY	611	200 - 1200	U/L		
TBIL	< 0.1	0.1 - 0.6	mg/dL		*
BUN	11	7 - 25	mg/dL		
CA	10.7	8.6 - 11.8	mg/dL		
PHOS	2.9	2.9 - 6.6	mg/dL		
CRE	0.7	0.3 - 1.4	mg/dL		
GLU	108	60 - 110	mg/dL		
NA+	150	138 - 160	mmol/L		
K+	3.7	3.7 - 5.8	mmol/L		*
TP	7.7	5.4 - 8.2	g/dL		
GLOB	3.9	2.3 - 5.2	g/dL		
HEM	1+				
LIP	0				
ICT	0				

5/10/2022 9:01 PM

Document

Discharge: A Blank Template



Heart and Soul Animal Urgent Care

315 NE Killingsworth St. Portland, OR 97211

pdxheartandsoul@gmail.com

503.749.9400

Toots Bailey

Tuesday, May 10, 2022

Diagnosis: Suspected periodontal disease causing decreased appetite - other possible rule-outs include pancreatitis, neoplasia/cancer, open

Diagnostics performed:

1. CBC/chemistry: no significant abnormalities

Diet Restrictions:

Please feed Toots softened food until he is able to see a veterinary dentist.

Exercise Restrictions:

Normal activity.

Monitoring:

Please monitor for vomiting, diarrhea, lethargy, inappetence, weakness, or any other concerning changes.

Recheck instructions:

Plan to recheck with us or your primary care provider if the above clinical signs are observed.

The dental clinic we discussed on the phone is called Forever Pet Dental - they have locations in Vancouver and Beaverton.

Thank you for entrusting Heart and Soul with the care of your beloved pet. Please give us a call if you have any questions or concerns.

Sarah Hunter, D.V.M.

